


Rams' Breeding Soundness Evaluation

*Year round management for rams that are fit
for successful reproduction*



October 2016

Whether you're preparing rams for artificial breeding or for natural mating, good, year round ram management is essential for success.



Fit sires for successful reproduction

Full Certification of Breeding Rams



Origin and
Breeding
Value

Screening
For Sexually
Transmitted
Diseases

Physical &
Reproductive
Organs
Examination

Sperm
Production
& Viability -
Serving
Capacity

This field guide aims to increase the awareness of small ruminant farmers in evaluating the mating ability of rams and on how to select and/or purchase good breeding males.

The examination of rams for mating ability is an important step towards improving flocks' fertility and avoiding disease transmission. The impact of addressing the rams' reproductive performance prior to the mating season is important as fifty percent of the reproductive potential of a flock is provided by the ram (McLaren, 1988). The rams should be monitored regularly during the year and not only during the mating season.

Do not neglect rams throughout the year and then expect them to perform during the mating season. A mature, fit, healthy ram can serve 40 or more ewes during a breeding season. An unthrifty, thin, sick ram is often sterile and will not settle any ewes. This ram will transmit diseases and/or will give bad descendants. Except for systematic, time-consuming analyses for sperm and laborious serving capacity tests, most of the problems adversely affecting the reproductive ability of rams can be easily detected through a careful physical examination (Mozo et al., 2015).

A community-selected ram in Bonga, Ethiopia



When selecting or purchasing

The breeding ram should have a known origin (non-contaminated flock and certified or at least known parents). A breeding soundness exam includes visual appraisal of general health and condition, as well as a soundness check on feet, legs, eyes, teeth, jaws, etc. When purchasing rams, a veterinary examination will be of great help to detect any health trouble. Buying a ram has a cost but if he brings in a disease, the expenses have just started!

A comprehensive examination of genital organs should be performed including a scrotal circumference measurement, testicle and penis examination. Where possible, males should be assessed for semen production and viability. Breeding soundness should be performed at least two months before mating to allow recovery of rams from pathologies or poor physical conditions.

Testing rams for diseases in Bako (Shambu CBBP site), Ethiopia



Feed males for fertility

To maximize testis mass and therefore quantity of sperm produced, males need to be fed a grain-based supplement each day for 8 weeks before mating. Concentrate-fed rams are prone to the precipitation of mineral elements in their urine. An important issue here is the concept of 'fit but not fat' – males that are overweight and do not get exercise can perform poorly, even when they have maximum testicular mass.

If the sheep flock is synchronized (use of hormones or by the ram effect) and instead of the males having to serve 5-6% of the females every day, as happens during an ordinary mating season, they might encounter as many as 30% of the females in estrus on some days.

In addition, rams should be sheared, treated for internal and external parasites and have their feet periodically examined (every two months for example) and - if needed for a good aplomb - trimmed and/or treated before turning in with the ewes.

Fit Awassi ram in the Jordan Badia

Energy allowance for breeding rams is 110-120% of the maintenance requirement. Metabolisable Energy for Maintenance is 93 Kcal/ kg of metabolic live weight ($\text{weight}^{0.75}$).



How to examine rams: the Do It Yourself way

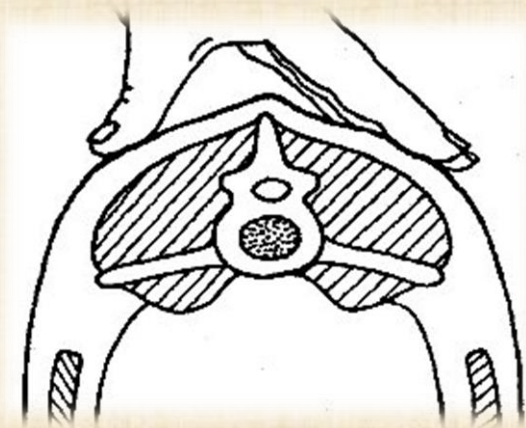


Body condition scoring (BCS)

Condition scoring is a simple effective technique that is worth adopting to determine feeding levels for rams. Frequent scoring with appropriate feeding:

- ✚ Minimizes welfare problems
- ✚ Reduces losses
- ✚ Maximizes longevity and mating success

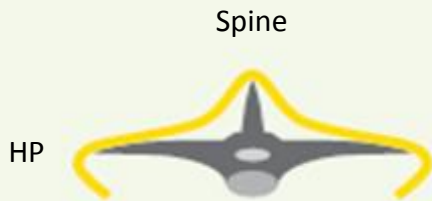
First assessment of the BCS should be carried out at least 2 months before the start of the mating season which allows sufficient time to correct the feeding regime and achieve target BCS. Rams are less hardy during the mating season and they are exposed to losses of BCS. Severe loss of condition during the mating period of up to two units of condition score endangers ram welfare and may predispose animals to respiratory disease and other infections.



*BCS assessment at
the lumbar region*



Body condition score grid



Spine

Score 1



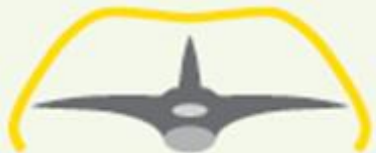Score 2



Score 3



Score 4



Score 5

Score 1: Spine prominent and sharp, fingers easily pass under horizontal processes (HP). ***Too thin, possibly diseased.***

Score 2: Spine prominent and smooth, fingers go under with pressure. ***Too thin, hard used rams, needs supplementary feeding.***

Score 3: Spine smooth and rounded, fingers need pressure to find ends. ***Optimum condition for mating.***

Score 4: Spine detected as a line, HP are not felt. ***Overfat.***

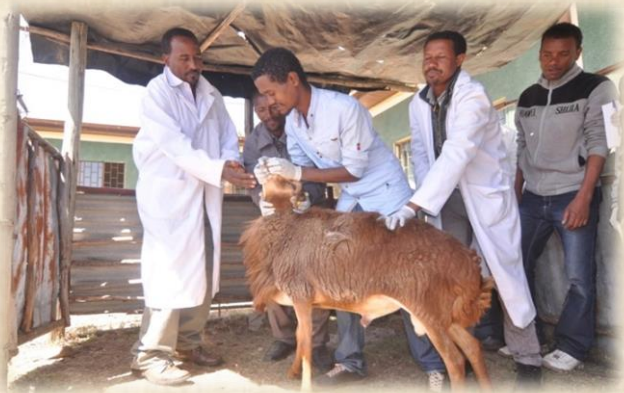Score 5: Spine not detectable, fat dimpled over spine, HP not detectable. ***Grossly overfat, mating ability compromised.***

Eyes and nose

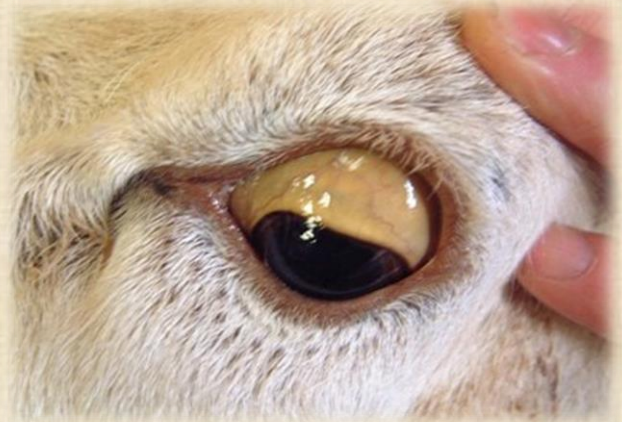Eyes: should be checked for any abnormality: presence of ocular lesion, anemia (pale conjunctiva), icterus (yellowish conjunctiva) or any eye discharge.

Nose: should be slightly humid with no discharge of any type. Its movements should be regular and not very perceptible.

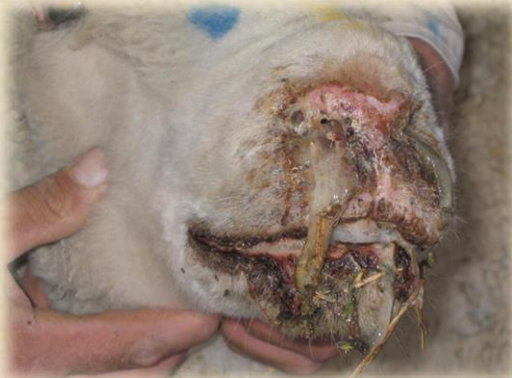Notify to the veterinarian any abnormal sign.



Abnormal pale conjunctiva

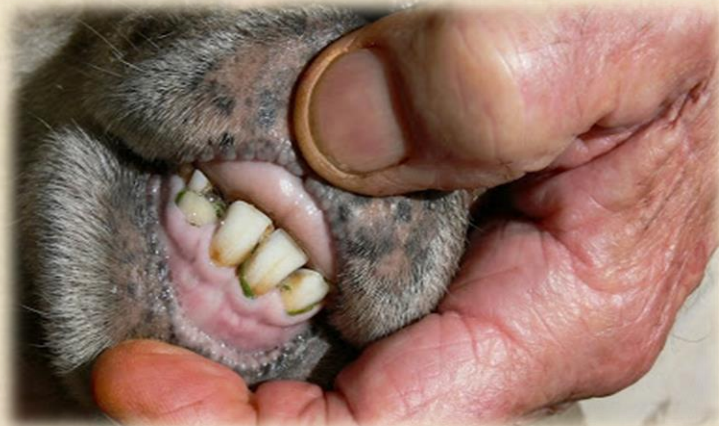

Severe nose discharge

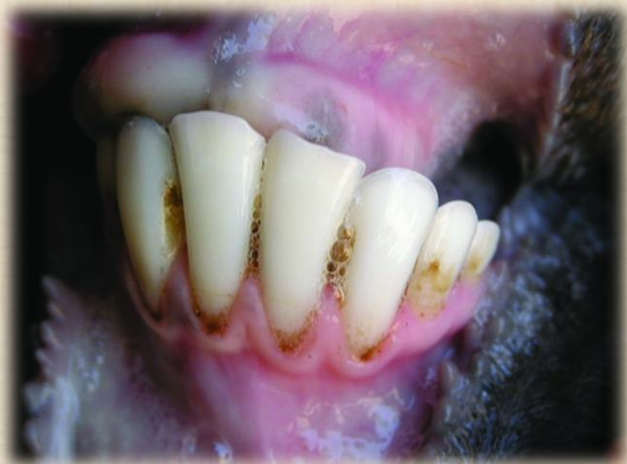

Mouth and Teeth

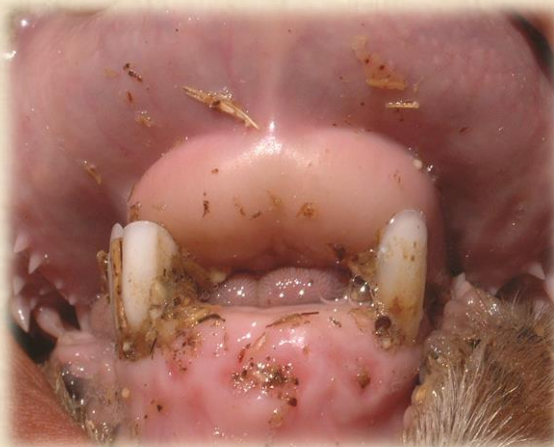Mouth should look normal with no symptoms of hyperkeratosis, any pustules or crusty lesions. Rams with several broken teeth or abnormal dentition causing difficulties in mastication should also be culled. This is particularly important for rams grazing dry, gross material.



*Partly broken teeth (upper panel)
and severe loss of dentition (lower
panel)*

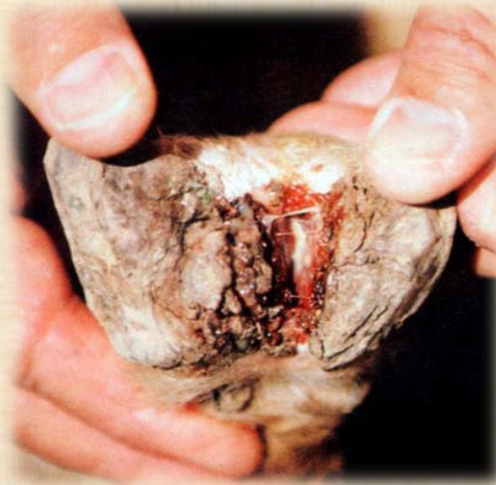

Normal dentition

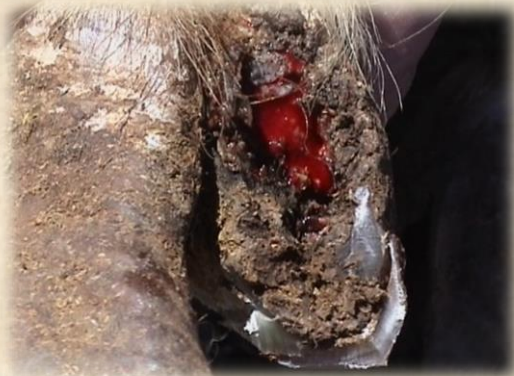

Feet and legs

Rams should have normal feet and legs for good standing positions during mating. Rams with lameness, foot rot, foot abscess, inter-digital growths or with non-trimmed hooves should be promptly treated.



Borrowed from S. Allan (2010); A chronic case of foot abscess with a discharging sinus



Infectious foot rot



Hooves trimming

The reproductive organs should be periodically examined and palpated

Scrotum

Scrotal circumference is an indicator of male fertility and serving capacity. Rams with normal, large scrotal circumference produce more and higher quality semen than rams of the same age and breed with small diameter. Daughters from sires with a larger testicle circumference are more fertile than females sired by males with a smaller circumference. The scrotum is first examined for dermatitis, wounds, edema...

When measuring scrotal circumference, it is important that both testicles are fully descended, with no deformation or adhesions to the skin.

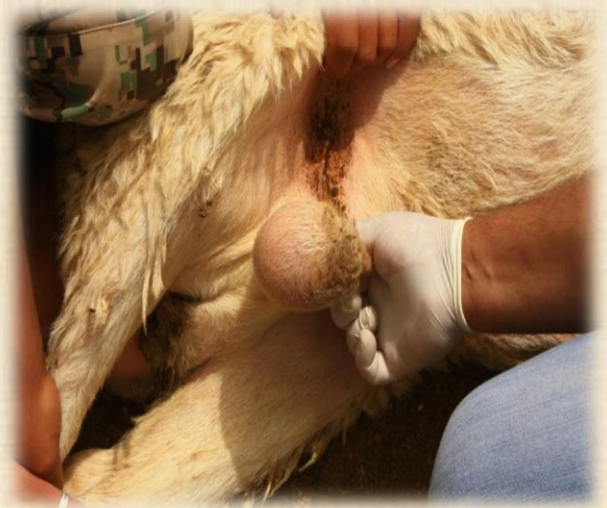The measurement is taken at the point of greatest circumference.



Guidelines for relationship between scrotal circumference and age of the ram are breed-dependent and therefore, such grids should be developed based on a large number of measurements using normal fit rams. For Ethiopian sheep breeds (Horro, Bonga and Menz), average scrotal circumference increases from 25 cm at 1 year of age to nearly 30 cm at 4 years of age. For larger breeds like Awassi, target scrotal circumference is 36-38 cm.

Testicles

Testicles should have the same size (symmetric) and move freely inside the scrotal bag; their mass should be firm, but not hard, with no indication of abscesses, injuries or any other condition. All these abnormalities affect fertility. All rams with testicular abnormalities, affecting even one testicle should be culled. Rams with only one testicle (monorchid) are sub-fertile and should not be kept for breeding even if you like their conformation and sexual aggressiveness.

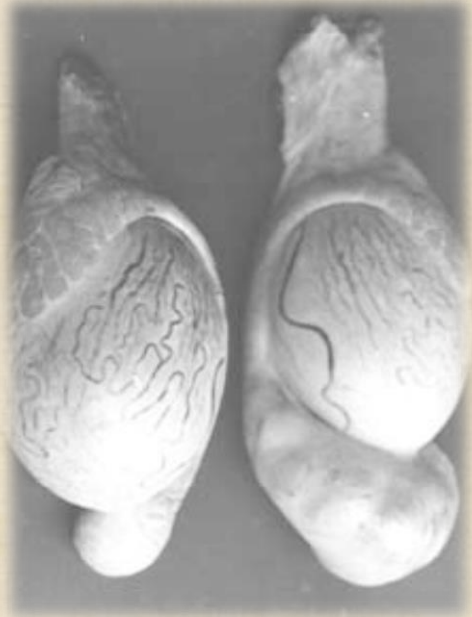

Palpation of the scrotal bag to assess testicles condition (left panel); Starting up in the cords above the testicles to examine the epididymis (right panel)

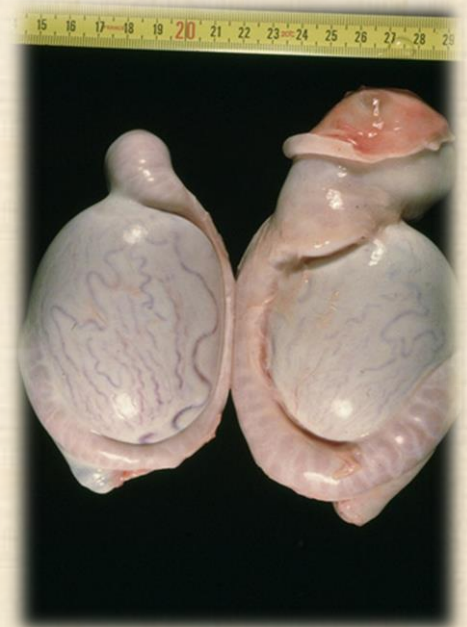
Epididymis

Epididymitis results in infertility and sterility in some affected rams. It also causes abortion in a variable percentage of ewes.

To examine the epididymis by palpation, rams can be examined in either a standing or sitting position. The neck of the scrotum is grasped between the thumb and forefingers, feeling for any swelling or lumps. Any lesions (lumps, abscess or any other lesion) in the spermatic cord or the head of the epididymis will be felt in this area.



Borrowed from J.W. Plant and J. Seaman (2007). Swellings visible on the tail of the epididymis of the right testes, the left testes is normal.



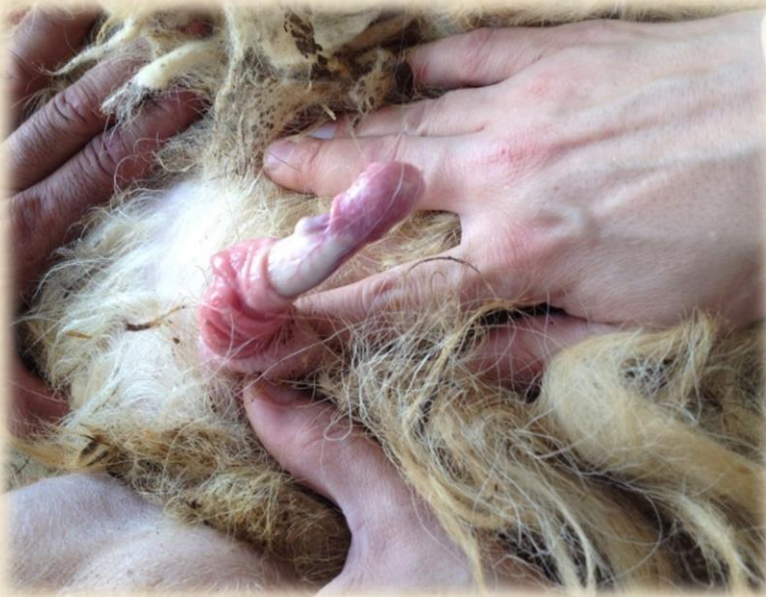Swellings visible on the whole epididymis of the right testes, the left testes is normal.

Penis & Prepuce

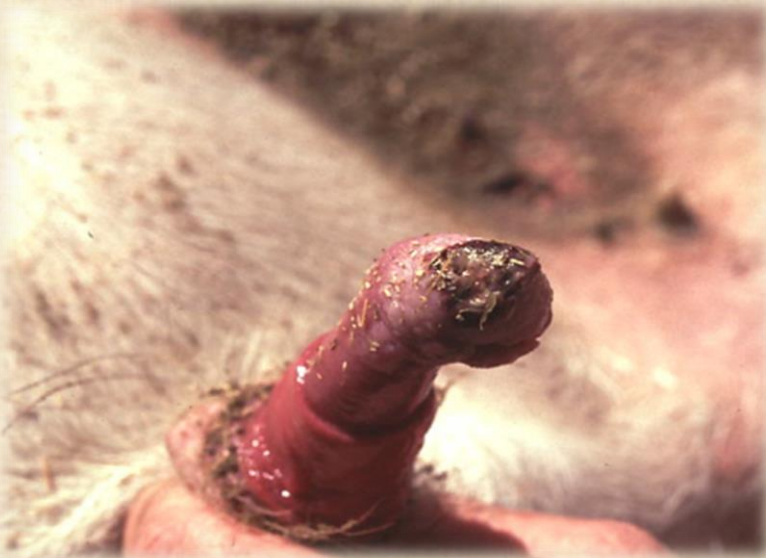The examination is best carried out when restraining the ram at its rump. The penis and prepuce should be examined to determine if there are indications of adhesion, pizzle rot (unhealthy combination of urine scald and bacterial growth on the prepuce) or any injury. Special attention should be paid to the preputial orifice for ulceration or inflammation. There should be no adhesions to the sheath or any signs of lesions of the gland, pus and abscesses. Rams with such abnormalities should be checked by a veterinarian before being used for reproduction. Indeed, rams with such alterations have a reduced willingness to mate because of pain when the lesions are in contact with the ewe.



Extruding the glans consists of grasping the sigmoid flexure firmly between the index and the thumb, pushing upwards towards the prepuce orifice and, at the same time, pushing the prepuce downwards



*Healthy prepuce and
glans (upper panel);
Prepuce showing lesions
indicative of posthitis
(lower panel)*

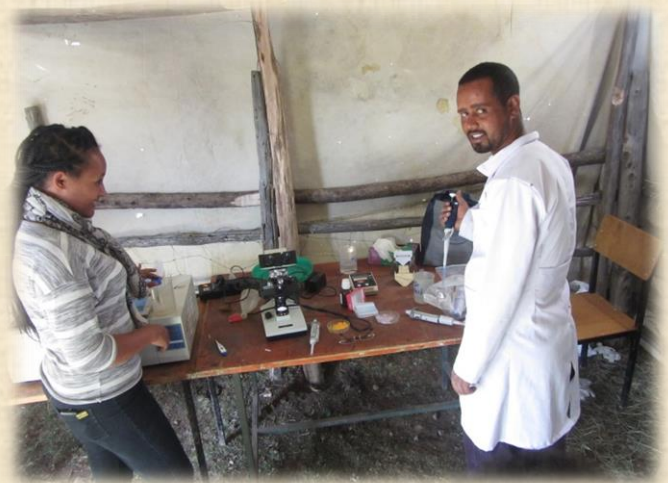

Semen assessment

Under veterinarian assistance, a semen sample can be collected from rams by using an electro-ejaculator or an artificial vagina. Collected semen is examined under a microscope to estimate the percent live spermatozoa ($> 70\%$), percent motility (> 3.5) and percent abnormal sperm cells ($< 15\text{-}20\%$). As this action is costly, several neighbor animal keepers may want to consider pooling their efforts to attract a veterinarian to a centralized location and perform the analyses for all the rams. Costs could then be shared between several producers.



Semen collection using artificial vagina



Field arrangement for instant semen evaluation

Ram lambs

Ram lambs can be used on a limited, but successful basis in a breeding program as they are source of valuable genetics. A well-developed 7 to 8 months old ram lamb can be bred to 15-25 ewes and even much more if being used in artificial insemination. Ram lambs need to be monitored closely during the breeding season to avoid domination by more experienced rams. One method that can be successfully used is to turn them in with the ewes only in the evening and at night. This requires daily observation in the beginning that yearling rams are effectively mating with sheep. For seasonal breeds (with a very restricted mating season in autumn), a treatment with melatonin for 7 to 8 weeks prior to the start of the mating season enhances semen production and quality and boosts sexual aggressiveness of yearling rams (Rekik et al., 2015). Each ram should receive 2 implants containing each 18 mg melatonin (Melovine® or Regulin®; CEVA animal health) 40 days prior to joining.

	Melatonin-treated	Control
Scrotal circumference (cm)	32.1±1.54	29.5±1.0
Sperm concentration (10 ⁹ spz ml ⁻¹)	5.87±0.703	4.61±0.654
Testosterone pulse frequency/8 h	3.45±2.24	1.25±1.0
Mount attempts/15 min	1.8±0.44	0.2±0.44

References and suggested further readings

Allan, S. 2010. Foot abscess in sheep. Primefact, 987: January 2010

McLaren, A. 1988. Ram fertility in South-West Scotland. British Veterinary Journal, 144: 45-54.

Mozo et al. 2015. Evaluating the reproductive ability of breeding rams in North-Eastern Spain using clinical examination of the body and external genitalia. BMC Veterinary Research, 11: 289

Plant, J.W., Seaman, J. 2007. Ovine brucellosis. Primefact, 472: June 2007.

Rekik et al. 2015. Melatonin administration enhances the reproductive capacity of young rams under a south Mediterranean environment. Animal Science Journal, 86 (7): 666-672.

Vipond, J., Morgan, C. 2008. Ram management and purchase. Scottish Agricultural College.

http://www.sruc.ac.uk/info/120109/beef_and_sheep_services/764/ram_management_and_purchase

Acknowledgements

This field manual is an output of the CGIAR Research Programs on Livestock and Fish and Dryland Systems.

This field manual was written by Mourad Rekik, Aynalem Haile, Barbara Rischkowsky and Muhi El Dine Hilali from ICARDA.

Critical review and advises by Wyburn, Deborah May (ILRI) are gratefully acknowledged.

The authors express many thanks to contributions from Hothaifa Ababneh (NCARE - Jordan); Jomana Hijazi (NCARE - Jordan); Ayele Abebe (Debre Birhan Research Institute – Ethiopia); Shenkute Goshme (Debre Birhan Research Institute – Ethiopia); Tesfaye Tadesse (Bako Agricultural Research Center – Ethiopia); Zelalem Abate (Bonga Research Institute – Ethiopia); Makhmud Shaumarov (ICARDA – Uzbekistan).

ICARDA Sheep and Goats Reproduction Range

